



Rapunzel Syndrome with Intestinal Obstruction: A Rare Entity

¹Dr. Mit Patel, Resident, Department of General Surgery, SSG Hospital, Vadodara, Gujarat, India

²Dr. Mukesh Pancholi, HOD, Department of General Surgery, SSG Hospital, Vadodara, Gujarat, India

³Dr. Digant Patel, Assistant Professor, Department of General Surgery, SSG Hospital, Vadodara, Gujarat, India

⁴Dr. Bharat Rathwa, Resident, Department of General Surgery, SSG Hospital, Vadodara, Gujarat, India

⁵Dr. Kalpesh Patel, Resident, Department of General Surgery, SSG Hospital, Vadodara, Gujarat, India

⁶Dr. Akshat Vyas, Resident, Department of General Surgery, SSG Hospital, Vadodara, Gujarat, India

Corresponding Author: Dr. Akshat Vyas, Resident, Department of General Surgery, SSG Hospital, Vadodara, Gujarat, India

How to citation this article: Dr. Mit Patel, Dr. Mukesh Pancholi, Dr. Digant Patel, Dr. Bharat Rathwa, Dr. Kalpesh Patel, Dr. Akshat Vyas, “Rapunzel Syndrome with Intestinal Obstruction: A Rare Entity”, IJMACR- February - 2025, Volume – 8, Issue - 1, P. No. 199 – 203.

Open Access Article: © 2025 Dr. Akshat Vyas, et al. This is an open access journal and article distributed under the terms of the creative common’s attribution license (<http://creativecommons.org/licenses/by/4.0>). Which allows others to remix, tweak, and build upon the work non-commercially, as long as appropriate credit is given and the new creations are licensed under the identical terms.

Type of Publication: Case Report

Conflicts of Interest: Nil

Abstract

An uncommon type of bezoar called a gastric trichobezoar is created when human hair, doll or animal hair, blankets, or carpets are swallowed. They typically appear in young women with trichotillomania and trichophagia who are emotionally unstable, despondent, or mentally challenged. They may result in bleeding, blockage, perforation, gastric ulcers, and abdominal pain. Here we present a case of 12-year-old female with Large Trichobezoar leading to Rapunzel Syndrome. The patient had trichotillomania and trichophagia for 7 years prior to presentation. Small bezoars should ideally be removed via a minimally invasive technique like endoscopic fragmentation. Nevertheless, despite the potential for severe scarring, open surgical extraction is

the only way to treat enormous trichobezoars, such as those found in Rapunzel syndrome. We report a case of Rapunzel syndrome with a large bezoar that was surgically removed.

Keywords: Trichobezoar, Rapunzel Syndrome, FOGD (flexible oral gastroduodenoscopy)

Introduction

An indigestible buildup of foreign substances un the gastrointestinal tract is called a bezoar. Gastric bezoars do not show symptoms until they are very large because of the stomach's vast capacity. The masses are categorized based on what they include. Fruit fibres or plants are called phytobezoars, milk is called lactobezoars, hair is called trichobezoars, and drugs are called pharmacobezoars [1]. Hair bundles in the stomach

or small intestine are a rare symptom of trichomoniasis. Psychiatric conditions including trichotillomania (hair pulling) and trichophagia (hair eating) are linked to trichobezoars in young women. An unusual kind of trichobezoar that spreads to the small intestine is called Rapunzel syndrome. Following endoscopic fragmentation, certain bezoar forms, such as tiny trichobezoars, can be eliminated [1]. However, very large trichobezoars, such as those in a patient with Rapunzel syndrome, are resistant to endoscopic fragmentation due to the dense hair mass. Therefore, these masses must be surgically removed, despite the large scars. Here, we report the case of Rapunzel syndrome with a large trichobezoar.

Case Report

Presenting complaints: A 12-year Female visited General Surgery OPD with complain of Abdominal Pain

Investigations:

Table 1:

USG Abdomen and Pelvis	Abdomen is full of bowel gas, Gall bladder minimally distended, Urinary bladder was minimally full of internal echoes and hyperechoic debris within.
CECT abdomen and pelvis	<p>Stomach appears distended and lumen filled with material having heterogenous mottled lucency and outlined by contrast on oral contrast administration which also extends into first and second part of duodenum causing distention of involved duodenal loop-suggest bezoar.</p> <p>Mild oedematous wall of distal jejunum with proximal mild dilatation of proximal jejunum and ileum shows internal air fluid level within – suggest possibility of subacute small bowel obstruction.</p> <p>Mild fluid in pelvis</p>

The stomach was enlarged and filled with a huge solid mass on the computed tomography (Figure 2) and plain abdominal x-ray (Figure 1)

for 8 days associated with nausea and vomiting with reduced appetite and not passing stool in the last 2 days. No associated complaints of Fever and burning micturition. The patient had no past medical history or Drug history or Surgical history. According to her parents, the patient chewed and pulled her hair before seven years. Upon admission, she displayed no symptoms of mental impairment, anxiety, or depression.

Per Abdominal examination: Abdomen was distended with pain in Right Iliac fossa. Tenderness and Rebound tenderness were present. Approx 10*7 cm firm to hard lump was present in epigastric and left hypochondrium region which moved minimally with respiration and had dull note on percussion.

Patient had pallor and had Tachycardia. Other systemic examination findings were unremarkable.

Figure 1: The simple abdominal x-ray. It displays a large soft tissue density of solid mass inside the stomach.

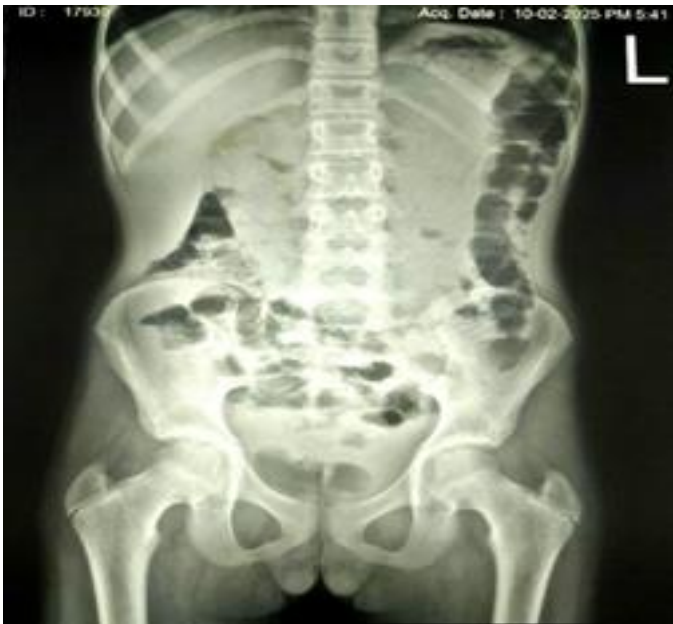
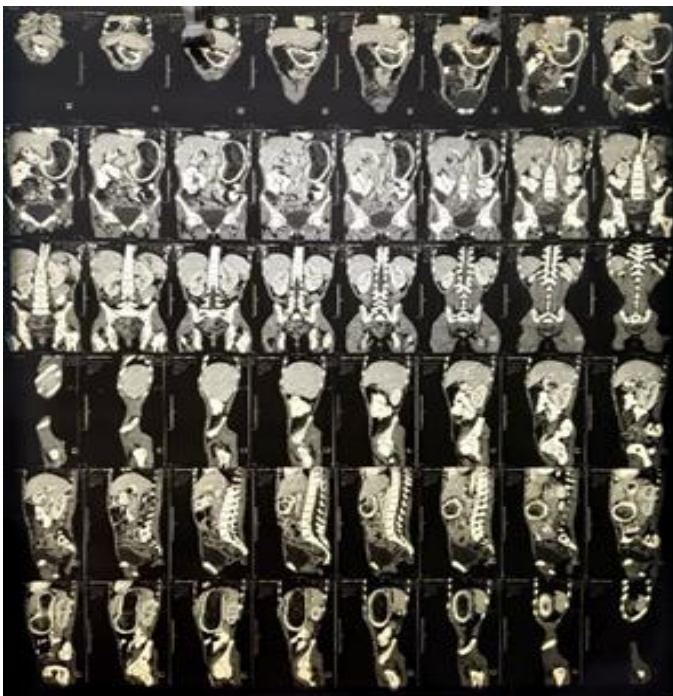
Figure 2: The abdominal computed tomography. The cavity of stomach is filled with a large heterogeneous mass.



Management: Patient was taken for Exploratory Laparotomy for small bowel obstruction. After confirming effect of General anaesthesia midline incision was kept over intestine. All solid organs, small

bowel and large bowel. Adhesion was found on distal ileum for which adhesiolysis was done. Inflamed appendix was found and appendicectomy was done. Necrosed omentum was present and tip of necrosed omentum was removed. Jejunum- Jejunum intussusception which was 15-20cm from Duodeno-jejunal junction was reduced. Incision was made over stomach and Trichobezoar was removed which was 8cm in diameter and 30cm in length and 850gram in weight. Stomach closure was done. Drain was placed on right side of the pelvis and abdominal closure was done. Dressing was applied and patient shifted to recovery room. No post operative complications were noted.



Figure 3: Specimen showing Trichobezoar same as size of kidney tray weighing 850gram

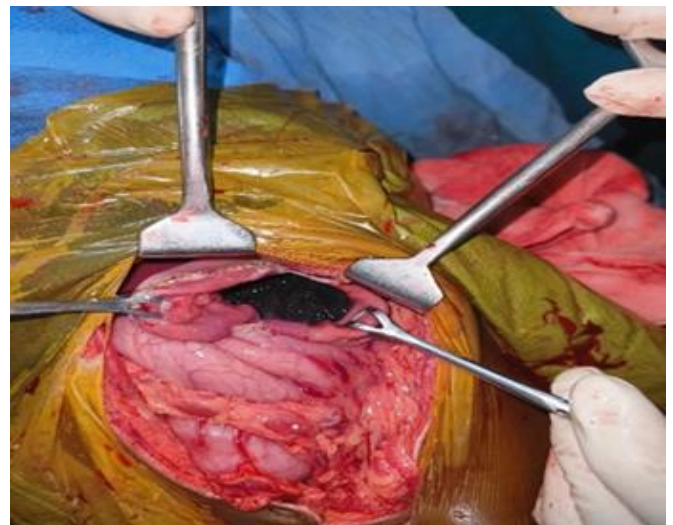


Figure 4: Intraoperative image of Trichobezoar inside stomach

Discussion

Trichobezoar is an uncommon ailment that primarily affects women (90%) and often manifests before the age of 30, with a peak incidence occurring between the ages of 10 and 19 [2]. Rapunzel syndrome is caused by trichomoniasis, which is most frequently found in the stomach but can also spread to the small intestine or even the transverse colon. It is in the stomach and bulbar region of our patient. Trichobezoar can either show up as transit disorders (33%) like diarrhoea or constipation, asthenia with weight loss (38%) or as epigastric discomfort (80%), abdominal pain (70%), nausea or vomiting (65%), or no symptoms at all [4-7]. Psychological pathologies are sometimes found such as psychomotor retardation or isolation but only 9% of children with trichobezoar would have real psychiatric problems [3]. A complication may be the mode of revelation of this pathology [7]. Acute pancreatitis, cholestasis, a gastric or small intestine perforation with peritonitis or subphrenic abscess, a mechanical gastric or small intestine occlusion, an upper digestive haemorrhage brought on by parietal ulcerations, a digestive fistula, or cholestasis could be the cause (Rapunzel syndrome) [8-11]. Clinical examination reveals a well-defined, firm, smooth, and movable abdominal mass in the epigastric region in 85% of cases. Additionally, alopecia may be observed [5, 7]. Our patient feels discomfort in her abdomen but neither alopecia nor an abdominal tumour. The trichobezoar's tangled hair pathognomonic can be seen by FOGD, which is still the preferred examination for diagnosis. Because it permits the endoscopic removal of tiny trichobezoars, it may occasionally be therapeutically useful [7]. But in most situations, including our patient's, this extraction is not feasible due to the size of the

trichobezoar, and any attempt involves a danger of severe oesophageal lesions. A thick or heterogeneous spherical mass with or without calcification protruding onto the stomach area may be visible on a plain abdominal X-ray.

An abdominal CT scan may reveal a heterogeneous, variable-volume mass that occupies nearly the whole stomach lumen and is made up of several concentric rings with varying densities dispersed throughout onion bulbs. The existence of microscopic air bubbles scattered throughout the mass and the lack of any attachment of the latter to the stomach wall are two pathognomonic and consistent indicators. [12] The literature has reported on several therapies. Therefore, some writers suggest using a lot of drinks in conjunction with using transit accelerators when there are little trichobezoars present, while others suggest endoscopic extraction. Other writers suggest that the trichobezoar be broken up endoscopically using a laser beam or by a mini explosion. These techniques not only leave patients untreated but also increase the danger of iatrogenic consequences, including intestinal or oesophageal blockage on a trichobezoar fragment. As a result, surgery is frequently used as treatment. Through surgery, the entire digestive tract can be examined, the gastric trichobezoar can be removed via gastrotomy, and any potential extensions (tail) or fragments that are obstructed distant from the stomach can be removed via one or more enterotomies [1, 13]. As an alternative to laparotomy, the laparoscopic approach has recently been suggested. Additionally, individuals frequently need to start receiving mental care [1].

Conclusion

Trichobezoar is an uncommon condition; USG Abdomen and CECT abdomen is useful for diagnosis

and esophagogastroduodenal fibroscopy is used to confirm the diagnosis. Radiological investigation, especially with a scanner, is crucial to identify more sites. Surgery is the preferred course of treatment, but patients' mental health care shouldn't be neglected.

References

1. Iwamuro M, Okada H, Matsueda K, et al. Review of the diagnosis and management of gastrointestinal bezoars. *World J Gastrointest Endosc* 2015; 7:336–345.
2. Ousadden A, Mazaz K, Mellouki I, Taleb KA. Gastric trichobezoar: a case report. *Ann Chir.* 2004 May;129(4):237–40. doi: 10.1016/j.anchir. 2004.02.008. [DOI] [PubMed] [Google Scholar]
3. Roche C, Guye E, Coinde E, Galambrun C, Glastre C, Halabi M, et al. Trichobezoar: about 5 observations. *Arch Pediatr.* 2005 Nov;12(11):1608–12. doi: 10.1016/j.arcped.2005.07.013. Epub 2005 Sep 27. [DOI] [PubMed] [Google Scholar]
4. Alouini R, Allani M, Arfaoui D, Arbi N, Tlili Graïess K. Gastroduodenojejunal trichobezoar. *Press Med.* 2005 Sep 24;34(16 Pt 1):1178–9. doi: 10.1016/s0755-4982(05)84146-6.
5. DeBakey M, Ochsner A. Bezoars and concretions: comprehensive review of the literature with analysis of 303 cases and presentation of eight additional cases. *Surgery.* 1938;4:934–63. continued in *Surgery.* 1939; 5:132-210. [Google Scholar]
6. Dalshaug GB, Wainer S, Hollaar GL. The Rapunzel syndrome (Trichobezoar) causing atypical intussusception in a child: a case report. *J Pediatr Surg.* 1999 Mar;34(3):479–80. doi: 10.1016/s0022-3468(99)90504-3. [DOI] [PubMed] [Google Scholar]
7. Qureshi NH, Morris K, McDevitt B. Trichobezoar: a condition to think of in case of mobile abdominal mass. *Ir Med J.* 1992;85:74. [PubMed] [Google Scholar]
8. Deslypere JP, Praet M, Verdonk G. An unusual case of trichobezoar: the Rapunzel Syndrome. *Am J Gastroenterol.* 1982 Jul;77(7):467–70. [PubMed] [Google Scholar]
9. Sinzig M, Umschaden HW, Haselbach H, Illing P. Gastric trichobezoar with gastric ulcer: MR findings. *Pediatr Radiol.* 1998 May;28(5):292. doi:10.1007/s002470050356. [DOI] [PubMed] [Google Scholar]
10. Faria AP, Silva IZ, Santos A, Avilla SG, Silveira AE. The Rapunzel syndrome has a case report: trichobezoar as a cause of intestinal perforation. *J Pediatr (Rio J).* 2000 Jan-Feb;76(1):83–6. doi:10.2223/jped.806.
11. Mehta M, Patel RV. Intussusception and intestinal perforations caused by multiple trichobezoars. *J Pediatr Surg.* 1992 Sep;27(9):1234–5. doi: 10.1016/0022-3468(92)90797-b. [DOI] [PubMed] [Google Scholar]
12. Hafsa C, Golli M, Mekki M, Kriaa S, Belguith M, Nouri A, et al. Giant trichobezoar in children: The role of ultrasound and esophagogastroduodenal transit. *J Pediatr puer.* 2005;18:28–32. [Google Scholar]
13. Singla SL, Rattan KN, Kaushik N, Pandit SK. Rapunzel Syndrome: a case report. *Am J Gastroenterol.* 1999 Jul;94(7):1970–1. doi: 10.1111/j.1572-0241.1999.01243.x. [DOI] [PubMed] [Google Scholar]