



## **Strangulated Obturator Hernia - A Case Report**

<sup>1</sup>Ms Shreya Atteri, PSGIMSR, Coimbatore

<sup>2</sup>Dr Sheik Asik Abu Sali, Assistant Professor, Department of General Surgery, PSGIMSR, Coimbatore

<sup>3</sup>Dr Rajesh Kumar S, PSGIMSR, Coimbatore

<sup>4</sup>Dr Jaya Pragadeesh G, PSGIMSR, Coimbatore

**Corresponding Author:** Dr Sheik Asik Abu Sali, Assistant Professor, Department of General Surgery, PSGIMSR, Coimbatore.

**How to citation this article:** Ms Shreya Atteri, Dr Sheik Asik Abu Sali, Dr Rajesh Kumar S, Dr Jaya Pragadeesh G, “Strangulated Obturator Hernia - A Case Report”, IJMACR- December - 2024, Volume – 7, Issue - 6, P. No. 165 – 168.

**Open Access Article:** © 2024 Dr Sheik Asik Abu Sali, et al. This is an open access journal and article distributed under the terms of the creative common’s attribution license (<http://creativecommons.org/licenses/by/4.0>). Which allows others to remix, tweak, and build upon the work non-commercially, as long as appropriate credit is given and the new creations are licensed under the identical terms.

**Type of Publication:** Case Report

**Conflicts of Interest:** Nil

### **Introduction**

Obturator hernia accounts for around 0.07%–1.0% of all hernias making it a rare type of abdominal hernia. It is responsible for 0.2%–1.6% of all cases of mechanical obstruction of the small bowel. Western studies indicate a much lower incidence in comparison to Asians. [1]. The hernial sac will pass through obturator internus, the obturator membrane, and obturator externus in that order, and therefore, lies deep and inferior to the pectineus muscle, superficial to the obturator externus. As this is a small opening in the pelvis, the probability for these herniae to get incarcerated and strangulated is higher compared to other herniae.

**Keywords:** Abdominal Hernia, Pelvis, Pectineus Muscle, Left Sided Colitis

### **Case Report**

We report a case of a 66 year old lady a known case of ulcerative colitis on treatment presented to the Emergency department of PSG Hospitals, Coimbatore with complaints of intermittent, dull aching type of right sided lower abdominal pain. Which was moderate in severity, aggravated on food intake and relieved on rest associated with multiple episodes of non-bilious vomiting. She also gives history of obstipation for three days. Per abdominal examination revealed visible intestinal peristalsis with mild distension, tenderness present over the right iliac fossa, suprapubic, and peri umbilical region, guarding present with absent bowel sounds. Per rectal examination shows collapsed rectum with faecal stained glove. Contrast Enhanced Computed Tomography (CECT) taken showed small bowel obstruction with herniated loop of mid ileum situated deep to pectineus muscle and superficial to

obturator externus muscle, short segmental stricture mid ileum suggestive of right sided obstructed Obturator Hernia with chronic left sided colitis(fig-1) and X-ray abdomen erect examination taken showed multiple air-fluid levels (fig-2).

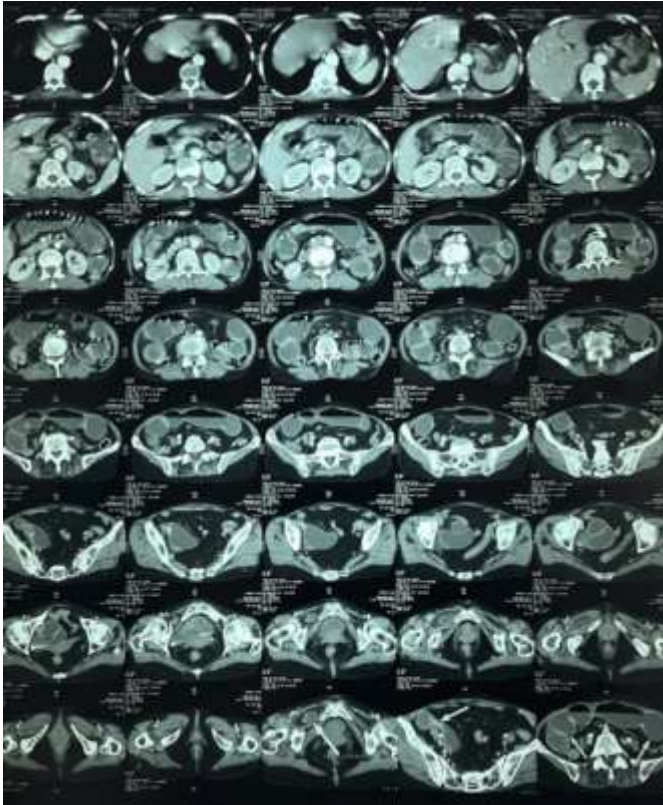


Figure 1: CECT showing right sided obstructed obturator hernia with acute small bowel obstruction with herniated loop of mid ileum situated deep to pectineus muscle and superficial to externus muscle short segmental stricture mid ileum suggestive of right sided obstructed Obturator Hernia with chronic left sided colitis.

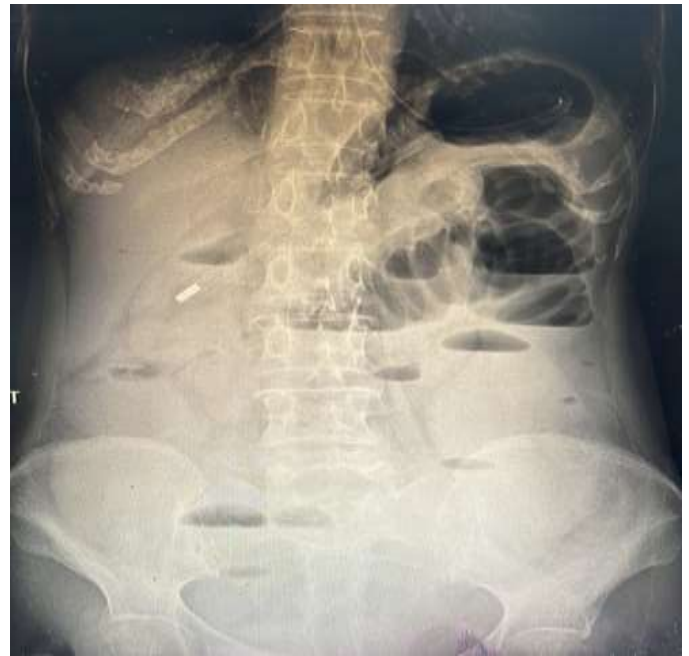

Figure 2: X-ray abdomen erect with multiple air-fluid level

Routine blood investigations showed anemia, hence she was transfused with unit PRBC pre operatively and she was taken up for Diagnostic Laparoscopy. After the peritoneal cavity was entered, right obturator hernia with gangrenous mid ileum as content was noted with Dilated proximal bowel loops and collapsed distal bowel loops. Multiple strictures were noted proximal to the obstruction. (Fig-3, Fig-4)

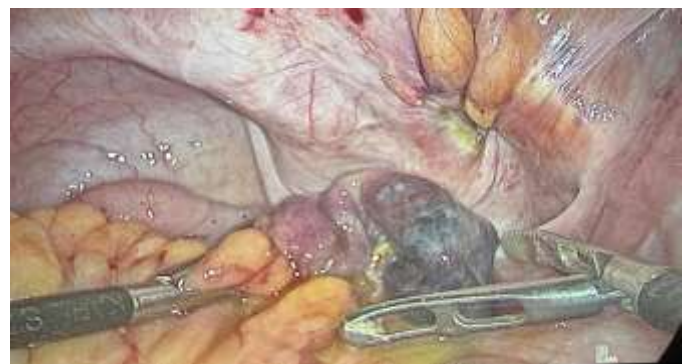

Figure 3: Intraoperative laparoscopic picture showing the gangrenous segment

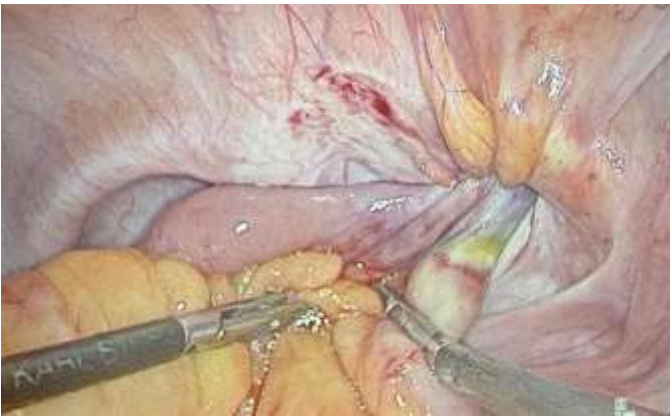

Figure 4: Intraoperative laparoscopic picture showing the site of hernia

Infra umbilical incision was made and bowel was delivered. 40cm of small bowel, including the gangrenous segment and adjacent strictures, was resected. (Fig-5).The resected segment showed transmural ischemic changes, ulceration and features of chronic ulcerative colitis (Fig-6)

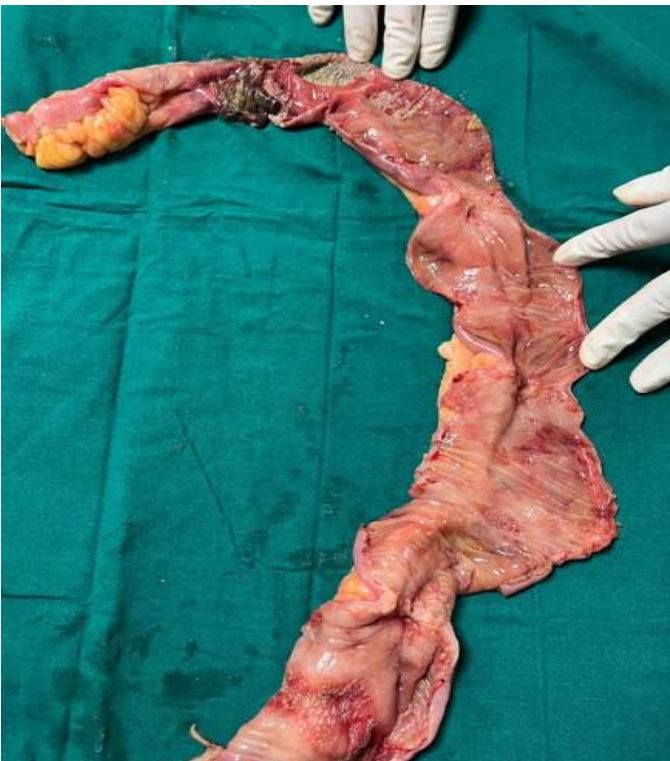

Figure 5: Resected segment of small bowel

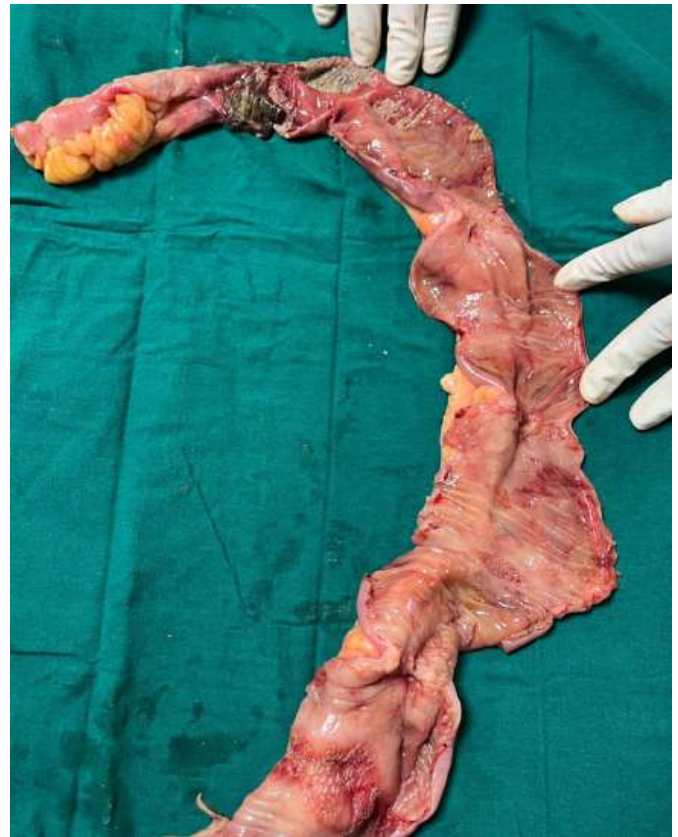

Figure 6: Resected segment showed transmural ischemic changes, ulceration and features of chronic ulcerative colitis.

Proximal end of the Jejunal stump was closed and an end to side ileojejunostomy was done. Open lower midline wound was closed in layers. Obturator defect was closed with 2-0 prolene. Thorough wash given and port sites were closed.

She was kept on mechanical ventilator post operatively in view of severe metabolic acidosis. She was transfused with one unit of PRBC for low hemoglobin. She was extubated on post-operative day one. Postoperative day 4, she was started on oral feeds which she tolerated well and she had regular bowel movements. She was discharged on post-operative day 6. On regular follow up she was found to be doing well.

## **Result**

Arnaud de Ronsil was the first to describe obturator hernia in 1724. It occurs mostly in elderly females and contributing factors are weight loss, pregnancy and neuropathies. [2]

As the signs and symptoms of obturator hernia are often nonspecific, making a preoperative diagnosis is difficult. When a case of obturator hernia is suspected, the preoperative diagnostic accuracy can be increased by using a pelvic CT scan, especially in elderly, debilitated women. Additionally, it also helps decrease surgical complications [3,4]

A midline laparotomy is the preferred approach for open hernia repair as a vast majority are diagnosed at laparotomy for small bowel obstruction. Excellent views of the obturator canal, nerve and vessels are obtained and a bowel resection can be easily performed with this approach [5]

Since the laparoscopic approach is minimally invasive and provides some benefits like less postoperative pain, less ileus, fewer pulmonary complications and a shorter hospital stay, it is a better alternative to repair an obturator hernia. [1]

## **Conclusion**

In the absence of signs related to the compression of the obturator nerve (Howship-Romberg sign), the clinical diagnosis of obturator hernia is difficult. This is because it occurs through the obturator foramen in the pelvis with no external lump that can be viewed on examination. A high degree of suspicion and CT imaging aid in the diagnosis of obturator hernia as seen in this case. Laparoscopic approach, as used in this case, is one of the preferred approaches to correct the defect in obturator hernia.

## **References**

1. S.K. Mantoo, K. Mak, T.J. Tan - Obturator hernia: diagnosis and treatment in the modern era - Singapore Medical Journal, 50 (9) (2009), p. 866
2. Computed tomographic diagnosis of obturator hernia and its surgical management: A case series Munoz-Forner Elena, Garcia-Botello Stephanie, Lopez-Mozos Fernando\*, Marti-Obiol Roberto, Martinez-Lloret Alfredo, Lledo' Salvador - International Journal of Surgery (2007) 5, 139e142
3. Ijiri R, Kanamaru H, Yojoyama H, Shirakawa M, Hashimoto H, Yoshino G. Obturator hernia: the usefulness of computed tomography in diagnosis. Surgery 1996; 119:137-40.
4. Kammori M, Mafune K, Hirashima T, Kawahara M, Hashimoto M, Ogawa T, et al. Forty-three cases of obturator hernia. Am J Surg 2004; 187:549-52.
5. Lobo DN, Clarke DJ, Barlow AP. Obturator hernia: a new technique for repair. J R Coll Surg Edinb 1998; 43:33-4.