



Functional Outcomes of Displaced Distal End Radius Fractures Managed with External Fixators in Adults

¹Dr Pradeep Sangnod, Assistant Professor, Department of Orthopaedic, Dr. Shankarrao Chavhan Govt. Medical College, Nanded, Maharashtra

²Dr. Rajesh Ambulgekar, Professor and HOD, Department of Orthopaedic, Dr. Shankarrao Chavhan Govt. Medical College, Nanded, Maharashtra

³Dr. Mohin Atram, Junior Resident, Department of Orthopaedic, Dr. Shankarrao Chavhan Govt. Medical College, Nanded, Maharashtra

Corresponding Author: Dr. Rajesh Ambulgekar, Professor and HOD, Department of Orthopaedic, Dr. Shankarrao Chavhan Govt. Medical College, Nanded, Maharashtra

How to citation this article: Dr Pradeep Sangnod, Dr. Rajesh Ambulgekar, Dr. Mohin Atram, “Functional Outcomes of Displaced Distal End Radius Fractures Managed with External Fixators in Adults”, IJMACR- October - 2024, Volume – 7, Issue - 5, P. No. 66 – 70.

Open Access Article: © 2024, Dr. Rajesh Ambulgekar, et al. This is an open access journal and article distributed under the terms of the creative common’s attribution license (<http://creativecommons.org/licenses/by/4.0>). Which allows others to remix, tweak, and build upon the work non-commercially, as long as appropriate credit is given and the new creations are licensed under the identical terms.

Type of Publication: Original Research Article

Conflicts of Interest: Nil

Abstract

Introduction: Lower end radius fractures are most common fractures of upper extremity. However, vast majority of fractures of the distal end of radius are articular injuries that result in disruption of either radiocarpal joint or distal radioulnar joint or both.

Methods: Although there is no approach superior over another in our study 30 patients with intra-articular distal radius fracture were treated with external fixator. The external fixator was maintained for 6-8 weeks followed by physiotherapy.

Result: The external fixator was maintained for range of 6-8 weeks. Duration of follow-up ranged from 6 to 10 months. At the final analysis of the outcome of the study excellent results were noted in 15 cases 50% cases,

good results were noted in 11 cases 36.66%, fair results were noted in 3 cases 10%, poor results were noted in 2 cases 6.66%

Conclusion: Comminuted intra-articular fractures at distal end of radius needs external fixator in order to have i. Achievement of stable fixation by minimal invasive technique. ii. Achievement of satisfactory anatomical reduction. iii. Achievement of early mobilization and over all good functional end results.

Keywords: External fixator, Distal end radius, DRUJ, ligamentotaxis

Introduction

All age groups experience distal radius fractures, which have a bimodal distribution. Due to high energy trauma in young adults and low energy falls in the elderly,

which are frequently linked to osteoporosis, they are most common in these populations.⁽¹⁾ Because of their lower bone density, women—especially those who have recently gone through menopause—are more likely to suffer distal radius fractures.⁽²⁾ They might be simple, non-displaced fractures or complex, comminuted fractures with severe displacement and instability; they are frequently the result of falls on an outstretched hand.⁽³⁾

De Palma (1952) demonstrated value of soft tissues that remains intact following fractures of distal radius Intra focal pinning originally was described in 1976 by Kapandji and has been used widely in Europe. Vidal et al (1977)⁽⁴⁾ coined the term ligamentotaxis. Various new techniques have been described recently for the treatment of distal radial fractures. Such as micro nail, combined internal and external fixation in situ screw placement, closed reduction and percutaneous injection of paste that forms carbonated apatite, low intensity pulsed ultrasound etc. External fixation is particularly useful for highly comminuted fractures, open fractures, and fractures with severe soft tissue injury.⁽⁵⁾ External fixation offers a reliable and minimally invasive method for stabilizing displaced distal radius fractures, providing good functional and radiological outcomes with a relatively low complication rate.

Method

The study was designed as a prospective observational study to evaluate the functional outcomes of displaced distal end radius fractures in adults managed with external fixators. The study was conducted at a tertiary health care center, specifically within the Orthopaedics Department.

Patients were recruited from both the outpatient department (OPD) and the emergency department,

ensuring the inclusion of both elective and urgent cases. The study was conducted over a period of 18 months. The extended follow-up allowed for the assessment of outcomes at multiple time points, including the critical phases of initial recovery, mid-term rehabilitation, and long-term functional integration. Study includes 30 patients in 18 to 65 age group with closed and compound distal end radius fracture with written informed consent. Patients with Neurodeficient, major head injury component, with co-morbidities, with immunodeficiency were excluded. Patients were evaluated and posted for operative procedure under general anaesthesia or brachial block.

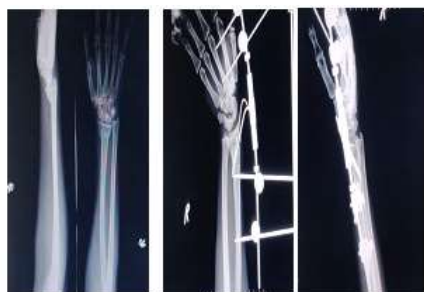
Results

Majority 36.66% patients were from 18-30 year of age, 33.33% patients were from 31-40 year of age, 16.66% were from below 41-50 years of age and minority 13.33% patients were from above 51-65 years of age. The mean age is 35.2 and standard deviation is 10.96. In this study as per mode of injury evaluated we had 1 case of fall from height 3.33%, 16 cases of road traffic accident 53.33%, 12 cases of self fall 40%, sports injury 1 case 3.33%. Majority 70% were patient having open fracture while 30% having closed fracture.

Functional outcome assessed by mean range of movements, ulnar deviation was 25.33 degree, radial deviation was 16.5 degree. 60, pronation was 71.16 degree, supination was 78 degree, palmar flexion was 61.16 degree and dorsal flexion was 59.66 degree. On evaluation of grip strength of the affected and not affected sides, an equal grip strength of the affected as the normal was noted in 27 cases 90%, but grip strength of the affected was weaker than normal in 6 cases 10%. Patients were assessed according to Gartland and Werley scoring. At the final analysis of the outcome of the study

excellent results were noted in 15 cases 50% cases, good results were noted in 11 cases 36.66%, fair results were noted in 3 cases 10%, poor results were noted in 2 cases 6.66%. There were no complications noted in 24 cases (80%), arthritis was found in 2 cases 6.66%, malunion was found in 2 cases 6.66%, 1 case of pin track infection and 1 case of pin loosening was found. In our study in 28 cases there was no any deformity found in post operative one year follow up .1 patient develop prominent ulnar styloid and 1 residual dorsal tilt found after one year.

Clinical photos



Pre-Operative X-Rays Post-Operative X-Rays

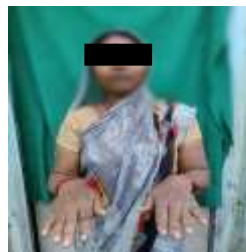

Post Operative Clinical Photo

Postoperative Clinical



Supination



Pronation



Palmer Flexion



Dorsiflexion



Grip Strength

Discussion

In this study as per mode of injury evaluated we had 1 case of fall from height 3.33%, 16 cases of road traffic accident 53.33%, 12 cases of self fall 40%, sports injury 1 case 3.33%. Chilakamary, V. K., Lakkireddy, M., Koppolu, K. K., & Rapur, S. (2016) has reported Number of cases due to road traffic accidents was 61.53% and 34.61% were due to falls⁽⁶⁾This study shows the distribution of respondents according to open fracture. Majority 70% were patient having open fracture

while 30% having closed fracture. These cases were classified on the basis of Gustilo- Anderson classification. In the study of Chilakamary, V. K., Lakkireddy, M., Koppolu, K. K., & Rapur, S. (2016) they included 7 cases (26.92%) of open fractures⁽⁵⁾. In present study as per Frykman type viii type of fractures was commonest with 19 cases followed by type vi 6cases 20%,type vii 3 cases 10% and type iii and iv one case each .

This study shows mean range of movements, ulnar deviation was 25.33 degress, radial deviation was16.5 degree.60, pronation was 71.16degress, supination was 78degress, palmar flexion was 61.16 degrees and dorsal flexion was 59.66 degrees. 105 In their study Thomas L, Sudheer U(2018) The palmar flexion improved from 37.7 degrees to 61.76 degrees over the one year follow up. The ulnar and radial deviation were 16.33 and 11.59 which improved to 34.43 and 26.27 respectively. The supination and pronation improved from 50.16 and 63.33 to 83.53 and 89.51 degrees respectively. These values clearly show an overall improvement in range of movement over a period of minimum one year follow up. Loss of circumduction was noted in 8 patients all more than 60 years except one. But this improved in all patients at one year follow up probably owing to the increase in overall range of movement. DRUJ pain was noted in 12 individuals the youngest of whom was 22 years and oldest 70 years. But this DRUJ pain persisted in even 9 patients at one year follow up.(7)

Study found no correlations between radiographic measures, osteoarthritis or PROMs. Most studies analysing osteoarthritis only include patients with intra-articular extension, which might explain the discrepancy with this study, where all fracture patterns were included. Furthermore, radiographic assessment of step-

off can be challenging (Watson et al., 2016). It is noteworthy that the incidence of radiocarpal osteoarthritis in this study is low (Kellgren– Lawrence grade 2–4), 106 which could contribute to the fact that our patients are restored to normal function 10 years after the fracture⁽⁸⁾ In their study Thomas L, Sudheer U (2018) Grip strength was reduced on the affected side to less than 60% of the normal side in 7 patients, all above the age of 50 yrs. It improved in all but 4 of them, all above 60 years⁽⁷⁾ Our study showed grip strength of the affected was weaker than normal in 6 cases 10%.

At the final analysis of the outcome of our study excellent results were noted in 15 cases 50% cases, good results were noted in 11 cases 36.66%, fair results were noted in 3 cases 10%, poor results were noted in 2 cases 6.66%. In the study of Chilakamary, V. K., Lakkireddy, M., Koppolu, K. K., & Rapur, S. (2016)Excellent to good result was achieved in 88.45% of our cases while fair result was achieved in 11.54 % of cases of which 1case had pintractinfection/loosening and the other 2 cases had malunion. There were no cases with Poor results in the present study. ⁽⁵⁾

In our study in 28 cases there was no any deformity found in post operative one year follow up. 1 patient develop prominent ulnar styloid and 1 residual dorsal tilt found after one year. In their study Thomas L, Sudheer U (2018) As far as residual deformity in the form of prominent ulnar styloid process, residual dorsal tilt, radial deviation of the hand, none of the patients had these at either fixator removal or at one year follow up. The subjective evaluation was on average 1.1, where 109 1 was good and 2 was fair. It improved to 0.96 where 0 was considered excellent and 1 good, showing an improvement in the average patient's subjective evaluation over a one-year period. The average available

wrist dorsiflexion at fixator removal was 24.63 degrees which improved to 57.27 degrees at the one year follow up mark. ⁽⁵⁾

Conclusion

The first treatment of plaster fixing and pins for distal end radius fractures has changed throughout time. Many wrist fractures can be successfully treated with the well-established fixator techniques of today. The external fixator is a simple, low-cost method. It effectively maintains fracture reduction in addition to avoiding stiffness and permitting early mobilization and hence well established functional outcome. Due to persistent ligamentotaxis, external fixator preserves the radial length better than open reduction and internal fixation with plating. Fixators work best in cases of severely comminuted fractures. This technique has very few complications

References

1. Chung KC, Spilson SV. The frequency and epidemiology of hand and forearm fractures in the United States. *J Hand Surg Am.* 2001;26(5):908-915.
2. Cummings SR, Melton LJ. Epidemiology and outcomes of osteoporotic fractures. *Lancet.* 2002;359(9319):1761-1767.
3. Court-Brown CM, Caesar B. Epidemiology of adult fractures: A review. *Injury.* 2006;37(8):691-697.
4. McCann PA, Clarke D, Amirfeyz R, Bhatia R. The cadaveric anatomy of the distal radius: implications for the use of volar plates. *Ann R Coll Surg Engl.* 2012;94(2):116-20.
5. Chilakamary, V. K., Lakkireddy, M., Koppolu, K. K., & Rapur, S. (2016). Osteosynthesis in Distal Radius Fractures with Conventional Bridging External Fixator; Tips and Tricks for Getting Them Right. *JOURNAL OF CLINICAL AND DIAGNOSTIC RESEARCH.* <https://doi.org/10.7860/jcdr/2016/16696.7048>
6. Nagi ON, Dhillon MS, Aggarwal S, Deogaonkar KJ. External fixators for intraarticular distal radius fractures. *Indian Journal of Orthopaedics.* 2004; 38: 19-22.
7. Thomas L, Sudheer U. Functional outcome of distal end of radius fractures treated with percutaneous pinning and dynamic bridging external fixator. *J. Evid. Based Med. Healthc.* 2018; 5(51), 3493-3497. DOI: 10.18410/jebmh/2018/712.
8. Schmidt V, Gordon M, Petterson A, Buttazzoni C, Seimersson A, Sayed-Noor A, Mukka S, Wadsten M. Functional outcomes are restored a decade after a distal radius fracture: a prospective long-term follow-up study. *J Hand Surg Eur Vol.* 2024 Mar;49(3):322-328. doi: 10.1177/17531934231194682. Epub 2023 Sep 8. PMID: 37684021; PMCID: PMC10882947.
9. Court-Brown CM, Caesar B. Epidemiology of adult fractures: A review. *Injury.* 2006;37(8):691-697.
10. Cooney WP. Management of Colles' fractures. *J Hand Surg Am.* 1989;14(1):137-139.