

## **Regaining the Confidence by Reattaching the Tooth Fragment –A Case Report**

<sup>1</sup>Dr.Sasalawad Shilpa, Assistant Professor, Government Dental College and Research Institute, Bangalore, India

<sup>2</sup>Dr. S K Srinath, Professor and HOD, Government Dental College and Research Institute, Bangalore, India

<sup>3</sup>Dr. Hemashree GS, Post Graduate Student, Government Dental College and Research Institute, Bangalore India

<sup>4</sup>Dr.Amina Zulfiqar, Post Graduate Student, Government Dental College and Research Institute, Bangalore India

**Corresponding Author:** Dr. Hemashree GS, Post Graduate Student, Government Dental College and Research Institute, Bangalore India

**How to citation this article:** Dr.Sasalawad Shilpa, Dr. S K Srinath, Dr. Hemashree GS, Dr.Amina Zulfiqar, “Regaining the Confidence by Reattaching the Tooth Fragment –A Case Report”, IJMACR- February - 2025, Volume – 8, Issue - 1, P. No. 243 – 246.

**Open Access Article:** © 2025 Dr. Hemashree GS, et al. This is an open access journal and article distributed under the terms of the creative common’s attribution license (<http://creativecommons.org/licenses/by/4.0>). Which allows others to remix, tweak, and build upon the work non-commercially, as long as appropriate credit is given and the new creations are licensed under the identical terms.

**Type of Publication:** Case Report

**Conflicts of Interest:** Nil

### **Abstract**

Traumatic dental injuries generally impair patients' quality of life and have an effect on their physical, mental, and social well-being. Crown fractures in the maxillary anterior teeth account for the majority of dental injuries reported, particularly in preschoolers and teenagers. In cases where the fractured segment is accessible and closely approximates the remaining tooth, reattaching the tooth fragment should be the initial treatment option instead of using a composite restoration because it preserves the natural appearance, functional success, and inherent tooth structure.

This case report presents the management of a complicated tooth fracture of maxillary right central incisor treated endodontically, followed by post and core, reattachment of the same fragment.

**Keywords:** Traumatic Dental Injuries, Crown Fracture, Post and Core, Fragment Reattachment.

### **Introduction**

Traumatic dental injuries(TDI)constitutes 5% of all injuries and it frequently affects children and adolescents.<sup>1</sup>Coronal fractures of permanent incisors represents around 18-22% of all the fractures of dental hard tissues, of which 28-44% are simple involving only enamel and dentin and 11-15% are complex involving enamel, dentin and pulp. Most commonly affected tooth is maxillary central incisors which comprises around 96% of these fractures, owing to their location in the maxillary arch.<sup>2</sup> TDI's if left untreated can lead to consequences such as development of periapical lesions, loss of mastication function and speech. Moreover it can negatively impact on social and psychological development of an individual due to its highly

unaesthetic appearance. Thus the treatment rendered should benefit the patient functionally and esthetically.

With several advancements in dental restorative techniques, various methods of treatment of complicated coronal tooth fractures are there and one such is reattachment of tooth fragment itself. This was introduced by Chosack and Eidelmann in 1964.<sup>3</sup> It is widely preferred method by dental practitioners due to its merits such as retaining of anatomical features, color and surface characteristics of tooth which eventually imbibe a positive psychological effect and long lasting aesthetics.<sup>[4]</sup> Fractured tooth reattachment by acid etch bonding technique was later given by Tennery in 1978.<sup>5</sup> This has been revolutionary since bonding being a simple and congruent adhesive restorative technique, increased the longevity of the restoration. This article presents tooth fragment reattachment by creating a vent in the coronal separated fragment followed by post and core for more enhanced retention.

### Case Report

A ten year old male patient reported to the Department of Pediatric and Preventive Dentistry with the chief complaint of broken upper front tooth during sports. clinical examination revealed Ellis class III fracture irt 11 (figure 1-A). A periapical radiographic examination revealed an oblique fracture of 11 involving enamel, dentin and pulp. No root resorption was evident in the radiographs. Medical history was non-contributory. He had brought the broken fragment one day after trauma stored in water and we shifted to saline and stored in refrigerator (figure 1-B). Since the parent had expressed an interest in use of the fractured fragment to restore the tooth, fragment reattachment procedure was decided as the treatment of choice.

It was planned to perform root canal treatment irt 11 followed by reattachment with fiber post reinforcement. Local anesthesia was administered. Fractured segment in relation to 11 was cleaned with 2% chlorhexidine solution and stored in isotonic saline solution. Root canal treatment was completed irt 11 and post space was prepared using Peeso reamers (figure 1-C). Fiber post of diameter 1.1 mm was selected (figure 1-D). Enamel bevelling of both tooth and broken fragment is given to increase the surface area. The prepared post space was etched for 15 seconds using 37% phosphoric acid. It was then rinsed thoroughly with water and excess water was removed with a cotton pellet. Bonding agent was applied on etched surface and post and light cured for 10 seconds. The post was then luted with resin cement extending into the vent created in the coronal separated fragment (figure 1-E, F, G, H). The patient was kept on periodic review and it was observed that both endodontic and restorative treatments remained clinically acceptable through each visit. The six months follow-up clinical evaluation revealed acceptable aesthetics and function with no periapical changes. (figure 2-A, B).

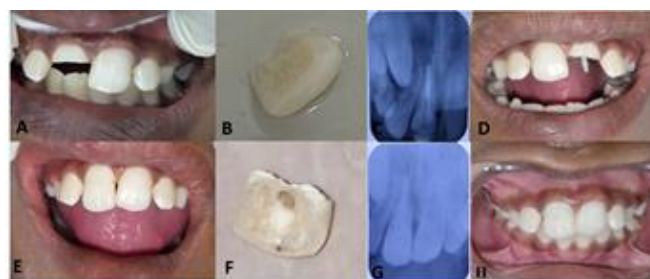


Figure 1: A-preoperative view (Ellis cl-3 fracture), B-fractured segment, C-root canal treatment followed by post space preparation, D-fiber post placement, E-approximation of fragment to the tooth, F-vent preparation in the coronal fragment, G-postoperative radiograph, H-postoperative clinical photo.

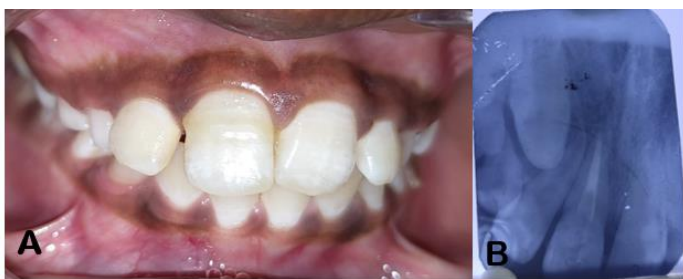

Figure 2: At six months follow up. A- Clinical image, B- Radiographic image

### Discussion

In this current era of booming advances in dentistry, aesthetic dentistry had carved its niche and popularity providing outstanding aesthetics which further enhances the overall wellbeing and self confidence in an individual and despite that one such treatment option available for complicated crown fractures is reattachment of the fragment tooth itself which overcomes the struggles of unmatched shade, differential tooth wear, and reproduction of natural texture and contour. Fragment reattachment success depends on various factors such as time elapsed after trauma, fracture site, rehydration status of fragment, size of fragment, direction of fragment line, vitality of tooth, invasion of biologic width and materials employed for fragment reattachment.<sup>6</sup> Fragment reinforcement can be done by various methods such as Simple reattachment, Enamel bevel, V-shaped internal enamel groove, Internal dentine groove, External chamfer, Overcontour, Vertical groove.<sup>7</sup> It is also reported that the use of a fiber post with fractured teeth, as it interlocks the two fragments, minimizes the stress on the reattached tooth fragment.<sup>[8]</sup> Fibre reinforced resin composite posts has advantage of similar modulus of elasticity as of dentin which provides even distribution of occlusal load.<sup>9</sup> Also, fibre reinforced resin composite post along with adhesive material acts as a monoblock thereby eliminates any inherent weak

interlayer interfaces which additionally enhances the fracture resistance along with other benefits such as minimal tooth preparation, lower chair time and enhanced esthetics.<sup>10</sup> In present case in addition to the preparation of the post space, a vent was created in the coronal separated segment and luted the post with resin cement. A similar technique has been recommended by Tosun et al. in reattachment using Ribbond material. By understanding the principles of fragment reattachment including proper case selection, fragment preparation and bonding techniques clinicians can provide patients with functional and esthetically pleasing results there by boosting the confidence of the child.(fig 3-A,B)

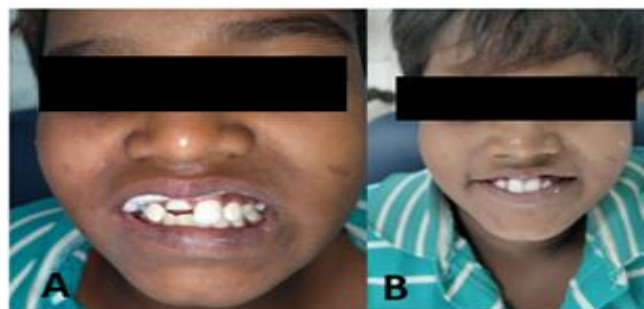

Figure 3: A- preoperative view, B- Regaining the confidence of child.

### Conclusion

Fragment reattachment is a relatively simple procedure and can be opted as a treatment modality in fractured teeth. This case demonstrates the feasibility and effectiveness of tooth fragment reattachment, providing a conservative and minimally invasive treatment option for patients with fractured teeth and also regaining the psychological confidence of child. This paper contributes to the growing evidence supporting the effectiveness of fragment reattachment.

### References

1. Levin L, Day PF, Hicks L, O'Connell A, Fouad AF, Bourguignon C,etal. International Association of Dental Traumatology guidelines for the management

- of traumatic dental injuries: General introduction. Dent Traumatol. 2020 Aug;36(4):309-313.
2. Maitin N, Maitin SN, Rastogi K, et al. Fracture tooth fragment reattachment Case Reports 2013; 2013: bcr 2013009183.
  3. Chosack A, Eidelman E (1964) Rehabilitation of a fractured incisor using the patient's natural crown: Case report. J Dent Child 71: 19-21.
  4. Thapak G, Arya A, Arora A: Fractured tooth reattachment: a series of two case reports. Endodontology. 2019;31:117-120.
  5. Tennery TN. The fractured tooth reunited using the acid-etch bonding technique. Tex Dent J. 1978 Aug; 96(8):16-7.
  6. Wadhvani CP. A single visit, multidisciplinary approach to the management of traumatic tooth crown fracture. Br Dent J. 2000 Jun 10;188(11):593-8.
  7. Fatima S, Rahman Z. Tooth Fragment Reattachment: Interim or a Permanent Solution? The Traumatologia. 2022;4(1-3):35-39.
  8. S. N. Akyuz and A. Erdemir, "Restoration of tooth fractures using fiber post and fragment reattachment: three case reports," European Journal of General Dentistry, vol. 1, no. 2, pp. 94–98, 2012.
  9. Nakamura T, Ohyama T, Waki T, Kinuta S, Wakabayashi K, Mutobe Y, et al. Stress analysis of endodontically treated anterior teeth restored with different types of post material. Dent Mater J. 2006; 25:145–50.
  10. Tay FR, Pashley DH. Monoblocks in root canals: A hypothetical or a tangible goal. J Endod. 2007;33:391–8.