

**Anaesthesia for A Patient with Eisenmenger Syndrome Undergoing LSCS**

<sup>1</sup>Dr Amithab S R, (M D Anesthesiology), Department of Anaesthesiology, GMC, Surat, Gujarat India.

<sup>2</sup>Dr. Tejal Chaudhari, Assistant Professor, Department of Anesthesiology, Government Medical College Surat, Gujarat.

<sup>3</sup>Dr Athira Venugopal, (MD Anaesthesiology), Department of Anesthesiology, GMC, Surat, Gujarat, India.

**Corresponding Author:** Dr Amithab S R (M D Anesthesiology), Department of Anaesthesiology, GMC, Surat, Gujarat India.

**How to citation this article:** Dr Amithab S R, Dr. Tejal Chaudhari, Dr Athira Venugopal, “Anaesthesia for A Patient with Eisenmenger Syndrome Undergoing LSCS”, IJMACR- April - 2025, Volume – 8, Issue - 2, P. No. 31 – 33.

**Open Access Article:** © 2025 Dr Amithab S R, et al. This is an open access journal and article distributed under the terms of the creative common's attribution license (<http://creativecommons.org/licenses/by/4.0>). Which allows others to remix, tweak, and build upon the work non-commercially, as long as appropriate credit is given and the new creations are licensed under the identical terms.

**Type of Publication:** Case Report

**Conflicts of Interest:** Nil

**Abstract**

**Introduction:** Eisenmenger syndrome is a cyanotic congenital heart condition with pulmonary hypertension and reversed shunt, often linked to septal defects. Pregnancy-related lowered systemic resistance intensifies right-to-left shunt, posing risks for both mother and foetus. Anaesthetic management during LSCS in Eisenmenger patients should prioritize stable hemodynamics, preventing hypotension that exacerbates shunting, adequate analgesia and ensuring proper lung gas exchange to reduce shunt and acidosis.

**Objectives:** To provide safe general anaesthesia during caesarean section to the obstetric patient with Eisenmenger syndrome.

**Methods:** A 24-year-old primigravida at 32 weeks of gestation presented to the emergency room with breathlessness, chest pain, and bluish nail discoloration lasting for 2 days. Her oxygen saturation was 80% on

room air. On admission, a 2D-ECHO revealed an ostium secundum atrial septal defect (ASD) with bidirectional shunting, pulmonary artery systolic pressure of 45mmHg and right ventricular dysfunction. The patient underwent a planned caesarean section at 34 weeks under general anaesthesia with Injection Lignocaine 2%, Injection Etomidate 0.3mg/kg, Injection Fentanyl 75mcg iv as induction agents. Intraoperatively, prophylactic intravenous dobutamine at 5-20mcg/kg/min and bolus of injection Esmolol was given as needed. Patient delivered a male child of 1.6kg with APGAR score of 6/10 and 8/10 at 1 and 5 minutes. She remained hemodynamically stable throughout the surgery and was extubated.

**Conclusion:** General anaesthesia technique with maintenance of hemodynamics as close to normal as possible can be used for successful management of patients with Eisenmenger syndrome.

**Keywords:** Eisenmenger syndrome, General anesthesia, LSCS

### Introduction

Eisenmenger syndrome is a cyanotic congenital heart condition with pulmonary hypertension and reversed shunt often linked to septal defects. The perioperative management of pregnant women with cardiac disease is challenging for anesthesiologist. Here we report the case of 24 year old primigravida patient presented with Eisenmenger syndrome taken up for elective LSCS under general anesthesia.

### Aims & Objectives

To provide safe general anesthesia during caesarean section to the obstetric patient with Eisenmenger syndrome.

### Case Report

A 24 year old primigravida at 32 weeks of gestation presented to the emergency room with complaints of breathlessness, chest pain, and bluish nail discoloration lasting for last 2 days. Her oxygen saturation on room air was 78-80%. On admission a 2D-ECHO was carried out and it revealed an ostium secundum atrial septal defect(ASD) with bidirectional shunt, pulmonary artery systolic pressure of 45mmHg and right ventricular dysfunction. She was posted for an elective caesarean section at 34 weeks of pregnancy considering the fetal lung maturation. On preanesthetic evaluation patient was vitally stable. On CVS examination S1 and S2 was audible with loud S2. other systemic examination was normal. All blood investigation was within normal limit. ECG of the patient showed right axis deviation with right ventricular hypertrophy with right bundle branch block. She was taken up for elective LSCS under ASA Class IV. After taking informed verbal and written consent, a wide bore 18G iv cannula secured

and ringer lactate was started. She was premedicated with Inj Metoclopramide 10mg iv. In operating room monitors were placed and baseline vitals noted. General anesthesia was administered after preoxygenation with 100% O<sub>2</sub> for 5min. General anesthesia was given with Inj Lignocaine 2%, Inj Etomidate 0.3mg/kg, Inj Fentanyl 75mcg iv as induction agents. Patient was intubated using Inj Succinylcholine 75mg iv. General anesthesia was maintained using oxygen, air, Inhalational sevoflurane, Inj intermittent scoline iv. Intraoperatively prophylactic intravenous dobutamine at 5-20mcg/kg/min and bolus of Inj Esmolol was given as needed. She delivered a male child of 1.6kg with APGAR score 6/10 and 8/10 at 1 and 5 minutes. The patient remained hemodynamically stable throughout the surgery and was reversed spontaneously and extubated uneventfully

### Investigation Chart

Hb- 17.20 g/Dl

PCV- 55.50%

TC- 6800/mm<sup>3</sup>

PLT- 86000/mm<sup>3</sup>

RBS- 125 mg/dL

Sr Creatinine- 0.77mg/dL

Sr Na+- 135mEq

Sr K+- 5.08mEq

**ABGA:** On room air

pH- 7.437

pCO<sub>2</sub>- 27.8 mmHg

pO<sub>2</sub>- 60.4 mmHg

HCO<sub>3</sub>- 18.3 mmol/L

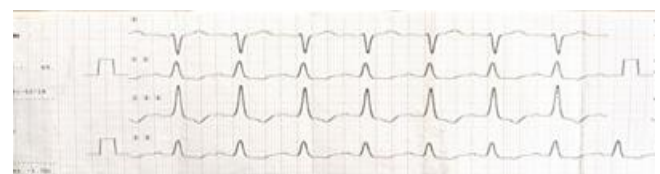


Figure 1:

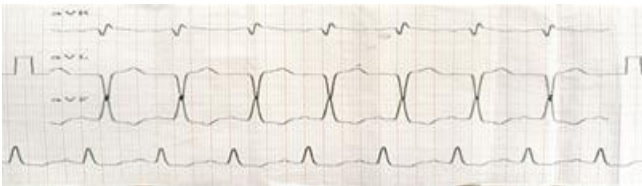

Figure 2:

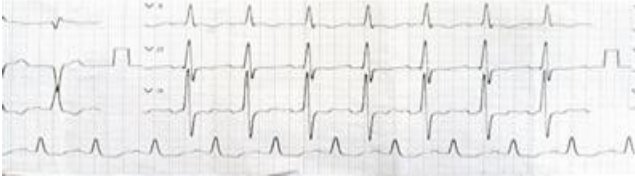

Figure 3:

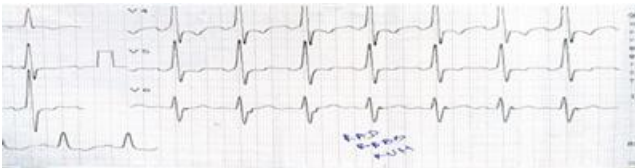

Figure 4:

### Discussion

The decreased systemic vascular resistance associated with pregnancy increases the degree of right to left shunting in Eisenmenger syndrome, thereby carrying substantial risk to both the mother and the foetus. The maternal mortality rate of pregnancy in the presence of Eisenmenger's syndrome is reported to be as high as 30–70%. The goals of anesthetic management of pregnant patient with Eisenmenger syndrome are to maintain stable hemodynamics, preventing hypotension that exacerbates shunting, adequate analgesia and ensuring proper lung gas exchange to reduce shunt and acidosis. The goal of monitoring is to detect sudden changes in the hemodynamics early so as to initiate appropriate treatment and prevent further complications. Epidural anaesthesia causes sympathetic blockade that reduces SVR. If SVR decreases without a concomitant decrease in PVR, the amount of right-to-left shunt increases. Therefore, in our case, we considered it undesirable to induce a sympathetic blockade that might have resulted in an increased right-

to-left shunt. To avoid this, we opted for general anaesthesia. The problems of general anaesthesia and positive-pressure ventilation are decrease in venous return and cardiac output. Hence, we decided to maintain the SVR with prophylactic dopamine infusion titrating to the effect. We avoided nitrous oxide because it is a potent pulmonary vasoconstrictor Oxytocin as a bolus causes direct vasodilation and reduces SVR with compensatory increase in the heart rate and cardiac output After the extraction of the baby, we chose to administer oxytocin as slow infusion

### Conclusion

General anaesthesia technique with maintenance of hemodynamics as close to normal as possible can be used for successful management of patients with Eisenmenger syndrome.

### References

1. T Gurusurthy, Radhesh Hegde, BS Mohandas in 2012 did a case study on Anaesthesia for a patient with Eisenmenger's syndrome undergoing caesarean section.
2. G. Fang, Y. K. Tian and W. Mei in 2011 did a case report on Anaesthesia Management of Caesarean Section in Two Patients with Eisenmenger's Syndrome.