

When Sepsis is Not Sepsis: Fatal EBV-Associated Secondary Hemophagocytic Lymphohistiocytosis in a Person Living with HIV

¹Dr Chithra Chandramohini Nath, Assistant Professor, Department of Clinical Microbiology, Travancore Medical College, Kollam

²Dr Rohini S Pillai, Senior Resident Doctor, Department of Clinical Microbiology, Travancore Medical College, Kollam

³Arun R.S, Tutor, Department of Clinical Microbiology, Travancore Medical College, Kollam

⁴Dr Shabeena, Senior Resident Doctor, Department of Clinical Microbiology, Travancore Medical College, Kollam

Corresponding Author: Dr Chithra Chandramohini Nath, Assistant Professor, Department of Clinical Microbiology, Travancore Medical College, Kollam

How to citation this article: Dr Chithra Chandramohini Nath, Dr Rohini S Pillai, Arun R.S, Dr Shabeena, “When Sepsis is Not Sepsis: Fatal EBV-Associated Secondary Hemophagocytic Lymphohistiocytosis in a Person Living with HIV”, IJMACR – May – 2026, Volume – 9, Issue – 3, P. No. 69 – 72.

Open Access Article: © 2026 Dr Chithra Chandramohini Nath, et al. This is an open access journal and article distributed under the terms of the creative common’s attribution license (<http://creativecommons.org/licenses/by/4.0>). Which allows others to remix, tweak, and build upon the work non-commercially, as long as appropriate credit is given and the new creations are licensed under the identical terms.

Type of Publication: Case Report

Conflicts of Interest: Nil

Abstract

Background: Hemophagocytic lymphohistiocytosis (HLH) is a life-threatening hyperinflammatory syndrome characterized by uncontrolled immune activation, commonly triggered by infections, malignancies, or autoimmune disorders. In immunocompromised individuals, particularly those living with Human Immunodeficiency Virus infection, HLH poses significant diagnostic and therapeutic challenges due to its clinical overlap with sepsis.

Case Presentation: We report a fatal case of secondary HLH associated with Epstein–Barr virus infection in a person living with HIV. A middle-aged male with a history of intravenous drug use presented with prolonged fever, respiratory distress, generalized oedema, and

lymphadenopathy. Initial evaluation for common tropical and opportunistic infections was unrevealing. Laboratory findings demonstrated cytopenia, markedly elevated ferritin levels, and deranged inflammatory markers. Bone marrow examination revealed features consistent with hemophagocytosis, supporting the diagnosis of HLH.

Management and Outcome: The patient was managed with antiretroviral therapy, intravenous immunoglobulin (IVIG), transfusion support, and intensive care measures. Despite aggressive treatment, his clinical condition rapidly deteriorated, progressing to refractory septic shock and multiorgan failure, ultimately resulting in death.

Conclusion: This case underscores the importance of early recognition of HLH in immunocompromised patients, particularly when clinical features mimic severe sepsis. Prompt diagnosis and timely initiation of HLH-directed therapy are critical, as delayed recognition is associated with high mortality.

Keywords: Hemophagocytic lymphohistiocytosis; HIV; Epstein–Barr virus; septic shock; immunocompromised host; case report

Introduction

Hemophagocytic lymphohistiocytosis (HLH) is a severe systemic inflammatory syndrome characterized by excessive immune activation and cytokine storm^{1,2}. It is broadly classified into primary (genetic) and secondary (acquired) forms. Secondary HLH is commonly associated with infections, malignancies, and autoimmune diseases⁴. Viral infections, especially Epstein–Barr virus (EBV), Cytomegalovirus, Arbovirus are among the most frequent triggers.

In persons living with HIV (PLWH), HLH is increasingly recognized but remains underdiagnosed due to overlapping features with opportunistic infections and sepsis⁷. The coexistence of HIV, EBV, and other co-infections further complicates diagnosis and management. Sepsis and HLH share overlapping clinical and laboratory features such as fever, cytopenia, coagulopathy, and organ dysfunction⁵. Differentiating between the two is crucial, as HLH requires immunomodulatory therapy in addition to antimicrobial treatment. This case report highlights a rare and fatal presentation of EBV-associated secondary HLH in a patient with HIV and hepatitis C virus (HCV) infection presenting as septic shock.

Case Presentation

A middle-aged male presented with fever for 15 days, cough with expectoration, progressive shortness of breath, abdominal pain, and swelling of bilateral lower limbs and massive ascitis. The fever was high grade, associated with chills and rigors. Respiratory symptoms progressed gradually, with dyspnoea reaching MMRC grade II–III and associated orthopnoea and paroxysmal nocturnal dyspnoea. Patient also complained of diffuse abdominal pain radiating to the back, partially relieved on bending forward. There was no history of vomiting, diarrhoea, or decreased urine output. He had a history of intravenous drug use but no known chronic illnesses. On examination, the patient was conscious and oriented. Vital signs showed tachycardia (126/min), tachypnoea (38/min), and fever (102.7°F). Oxygen saturation was maintained on room air. General examination revealed pallor, clubbing, generalized lymphadenopathy (cervical, axillary, inguinal), and pedal oedema. Respiratory system examination showed bilateral wheeze. Abdominal examination revealed diffuse tenderness, guarding, hepatosplenomegaly, and ascites.

Microbiological workup for tropical infections including malaria, dengue, typhoid, leptospirosis, and scrub typhus was negative. Blood and urine cultures showed no growth. Serological evaluation revealed HIV infection along with hepatitis C virus (HCV) co-infection. EBV viral load was significantly elevated (30,230 copies), indicating active infection. Hepatitis B infection was ruled out. Radiological imaging showed hepatosplenomegaly, gross ascites, bilateral pleural effusion, and multiple enlarged lymph nodes suggestive of infective or inflammatory aetiology (Fig:2 &3).

Bone marrow biopsy revealed hypercellular marrow with megakaryocytic hyperplasia, increased histiocytes,

reactive plasmacytosis, and dyserythropoiesis, suggestive of an inflammatory or infective process (Fig:1). Laboratory findings included bicytopenia (anaemia and thrombocytopenia), hypoalbuminemia, hyponatremia, and elevated inflammatory markers. Direct Coombs test was positive. Twenty-four-hour urine protein was 1620 mg/day. The HScore was calculated to be 192, which is strongly suggestive of HLH³. The patient fulfilled HLH-2004 diagnostic criteria².

Based on clinical presentation, laboratory findings, bone marrow examination, and virological evidence, a diagnosis of septic shock with HIV infection, HCV co-infection, EBV-associated secondary HLH was established.

The patient was admitted to the intensive care unit and managed for septic shock with broad-spectrum antibiotics, fluid resuscitation, and organ support. Antiretroviral therapy (ART) was initiated during hospitalization. Given the high suspicion of HLH, intravenous immunoglobulin (IVIG) was administered for 5 days. Supportive care included transfusions of packed red blood cells, fresh frozen plasma, and platelet concentrates. Invasive procedures such as pleural or ascitic tapping were deferred due to severe thrombocytopenia. Multidisciplinary management involving infectious disease specialists, haematologists, nephrologists, and intensivists was undertaken.

Despite aggressive treatment, the patient's condition deteriorated with worsening respiratory distress and altered sensorium. He required intubation due to poor neurological status. The patient developed cardiac arrest, was initially revived, but subsequently had recurrent arrest and could not be resuscitated.

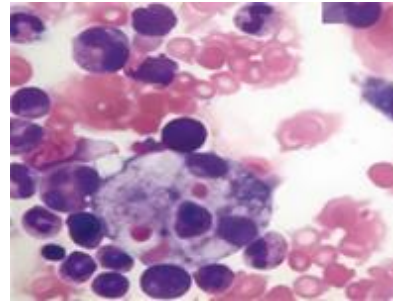


Figure 1: H&E staining of Bone marrow aspirate revealed activated histiocytes exhibiting prominent hemophagocytosis, with engulfment of erythrocytes, consistent with features suggestive of HLH

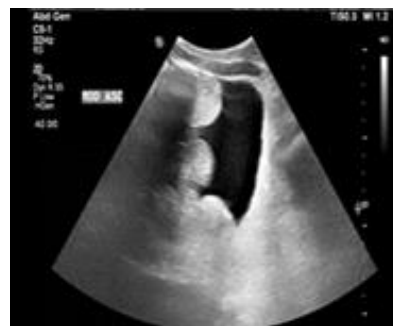

Figure 2: Ultrasound abdomen demonstrates moderate volume ascites with internal echogenic debris, suggestive of complex (exudative) ascites.

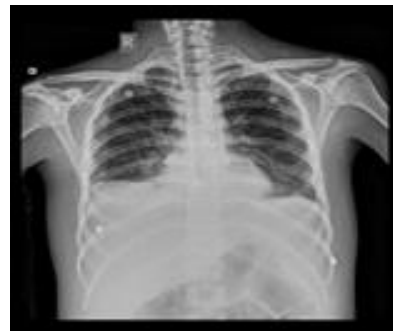

Figure 3: Chest radiograph demonstrates bilateral diffuse perihilar and basal air-space opacities with mild bilateral pleural effusion.

Discussion

HLH is characterized by uncontrolled activation of macrophages and lymphocytes, leading to cytokine storm and multiorgan failure^{2,8}. EBV is one of the most common infectious triggers of HLH and is associated

with aggressive disease ^{4,6}. In HIV-infected individuals, HLH may be precipitated by opportunistic infections, immune reconstitution inflammatory syndrome (IRIS), or malignancies ⁷. The coexistence of multiple infections, as seen in this case, significantly worsens prognosis.

The diagnostic challenge lies in differentiating HLH from severe sepsis, as both conditions share similar features ⁵. Scoring systems such as HScore and HLH-2004 criteria are valuable tools in early diagnosis ^{2,3}. Management involves treating the underlying trigger and controlling hyperinflammation. Therapies include corticosteroids, etoposide, IVIG, and supportive care ⁶. However, mortality remains high, especially in critically ill and immunocompromised patients ^{9,10}. This case underscores the importance of early suspicion of HLH in patients with persistent fever, cytopenias, and organomegaly, particularly in HIV-positive individuals.

Conclusion

Secondary HLH is a rare but fatal complication in immunocompromised patients. EBV-associated HLH in PLWH presents significant diagnostic and therapeutic challenges. Early recognition, prompt initiation of therapy, and multidisciplinary care are essential, although outcomes remain poor in advanced disease.

References

1. Risdall RJ, McKenna RW, Nesbit ME, et al. Virus-associated hemophagocytic syndrome. *Cancer*. 1979.
2. Henter JJ, Horne A, Aricó M, et al. HLH-2004 diagnostic and therapeutic guidelines. *Pediatr Blood Cancer*. 2007.
3. Fardet L, Galicier L, Lambotte O, et al. Development and validation of the HScore. *Arthritis Rheumatol*. 2014.

4. Roupael NG, Talati NJ, Vaughan C, et al. Infections associated with HLH. *Clin Infect Dis*. 2007.
5. Schram AM, Berliner N. How I treat HLH in adults. *Blood*. 2015.
6. La Rosée P, Horne A, Hines M, et al. Recommendations for HLH in adults. *Blood*. 2019.
7. Ramos-Casals M, Brito-Zerón P, López-Guillermo A, et al. Adult HLH. *Lancet*. 2014.
8. Jordan MB, Allen CE, Weitzman S, et al. How I treat HLH. *Blood*. 2011.
9. Machowicz R, Janka G, Wiktor-Jedrzejczak W. HLH: diagnostic and therapeutic challenges. *Br J Haematol*. 2017.
10. Otróck ZK, Eby CS. Clinical characteristics and outcomes of HLH. *Clin Adv Hematol Oncol*. 2015.